

# Case Study: Facial Burn & Diaper Rash

PCCA PracaSil™-Plus

Pediatrics

**PHARMASAVE**

FALLOWFIELD PHARMASAVE

COMPOUNDING PHARMACY  
& HOME HEALTH CARE CENTRE

(613) 823-3500

WWW.BARRHAVENPHARMACY.COM

**Summary:** PracaSil-Plus, a proprietary anhydrous silicone base, was applied topically on an infant's facial scalding burn and on a toddler's diaper rash, resulting in considerable progress in both pediatric case studies.

**Case Description (1):** A 5-month-old infant was severely scalded with a liquid on the face resulting in a major second degree burn. Following the incident, PracaSil-Plus was advised to be applied twice daily, in addition to a sterile bacitracin ointment. After eight days, there was a considerable progress of the infant's facial burn, as shown in the figures below.

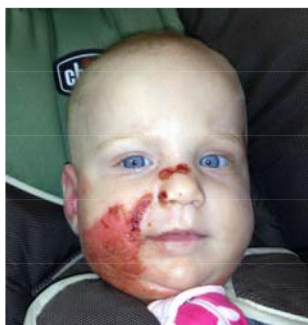

Figure 1. Infant facial burn (before PracaSil-Plus)

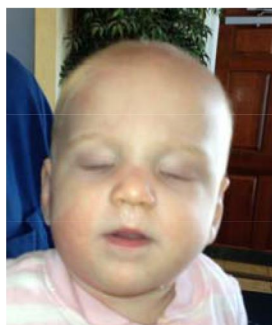

Figure 2. Infant facial burn (8 days after PracaSil-Plus)

**Pharmacist Report:** Eight days after the treatment, the father came back to my pharmacy with the baby and my staff was about to cry. The father was absolutely blown away with the results and we were, too.

**Case Description (2):** The caregivers of a 15-month-old toddler suffering from diaper rash had tried several over-the-counter topical products without success. The condition got worse with time resulting in increasing pain and discomfort for the toddler. The caregiver was then advised to apply PracaSil-Plus two to four times per day at diaper change. After 48 hours, there was an overall improvement of the toddler's diaper rash, as shown in the figures below.

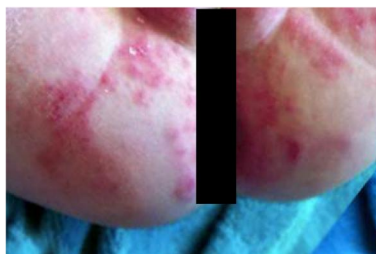


Figure 3. Toddler diaper rash (before PracaSil-Plus)

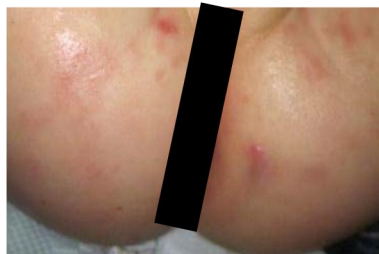

Figure 4. Toddler diaper rash (48 hours after PracaSil-Plus)

**Caregiver Report:** PracaSil-Plus was applied only twice in the first day and we still got amazing results. It worked so quickly – it took away the pain almost immediately. We are very happy!

**Acknowledgements:** Case Description (1) was reported by Mark Binkley, a PCCA Member of 30 years. Case Description (2) was reported by the grandmother of the patient, Cathie Berg, a PCCA Member of 27 years. PCCA Science is grateful for the valuable information shared by both Members.

**Introduction:** PracaSil-Plus is a proprietary anhydrous silicone base designed to be applied topically in scar therapy treatment (PCCA, 2013a). Silicones have been widely used for their occlusion and hydration properties, which are essential in scar management (Widgerow *et al.*, 2000; Mustoe, 2008). PracaSil-Plus also contains Pracaxi oil, extracted from the oilseed plant *Pentaclethra macroloba*, which has several medicinal applications including skin regeneration and healing (Costa *et al.*, 2013). PracaSil-Plus may be used alone or as a base for the incorporation of active substances in scar therapy treatment (PCCA, 2013a).

**Research Studies:** The efficacy of PracaSil-Plus in scar therapy treatment was evaluated by visual and instrumental methods in an eight-week, randomized, double-blind, controlled pilot trial conducted on eleven adult Caucasian subject volunteers. PracaSil-Plus showed qualitative and quantitative improvements in the following scar attributes: scar length, scar color/pigment intensity, scar texture/smoothness/roughness, and overall appearance in both old scars and new scars (PCCA, 2013b).

## References:

- Costa, M., Muniz, M., Negrao, C., Costa, C., Lamarao, M., Morais, L., Junior, J. and Costa, R. (2013) 'Characterization of *Pentaclethra macroloba* oil', *Journal of Thermal Analysis and Calorimetry*, 16 January 2013 [Online].
- Mustoe, T. (2008) 'Evolution of silicone therapy and mechanism of action in scar management', *Aesthetic Plastic Surgery*, 32 (1), p.82-92.
- PCCA (2013a) *PracaSil-Plus*. Available at: <http://www.pccarx.com/pcca-products/pcca-exclusives/bases/PracaSil-plus> (Accessed: 17 May 2013).
- PCCA (2013b) 'Efficacy of PracaSil-Plus in scar therapy treatment: a randomized, double-blind, controlled pilot trial', *Technical Report: 2TR0513*.
- Widgerow, A., Chait, L., Stals, R. and Stals, P. (2000) 'New innovations in scar management', *Aesthetic Plastic Surgery*, 24 (3), p.227-234.

Click the QR to see more PCCA studies and reports.

