

Case Study: Ankle Scars (Old & New)

PCCA PracaSil™-Plus

Summary: PracaSil-Plus, a proprietary anhydrous silicone base, was applied topically on ankle scars (old & new) and an overall improvement of both ankle scars was observed in a very short period of time.

Case Description (1): A type 1 diabetic 57-year-old woman fractured her ankle during a ski accident in March 2009. The patient underwent three reconstructive surgeries between 2009 and 2012, which resulted in three ankle scars. After the application of different products, the patient was still unsatisfied with the resulting unaesthetic scars. In April 2013, it was suggested the patient apply PracaSil-Plus twice daily on the old scars. Figures 1 and 2 (below) show the overall appearance of one of the patient's old scars, before (left) and one week after (right) the application of PracaSil-Plus.

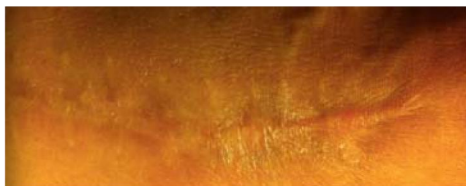

Figure 1. Patient old ankle scar (before PracaSil-Plus)

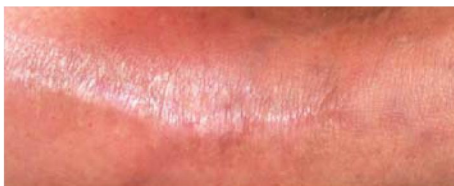

Figure 2. Patient old ankle scar (one week after PracaSil-Plus)

Patient Report: *In only one week I had incredible improvements in the overall appearance of my scars. The thickness almost completely disappeared, the dark color faded and the skin softened. I am very impressed with the results obtained.*

Case Description (2): A 50-year-old woman diagnosed with osteochondritis dissecans of the right talus went in for osteochondral allograft surgery, for the second time, in March 2013. The patient was advised to wait 10 days, following the removal of the stitches, before applying any topical scar treatments. After this period, the patient initiated treatment with (only) PracaSil-Plus twice daily for two weeks, lightly massaging into and around the scar area. Figures 3 and 4 (below) show the overall appearance of the patient's new scar, before (left) and two weeks after (right) the application of PracaSil-Plus.

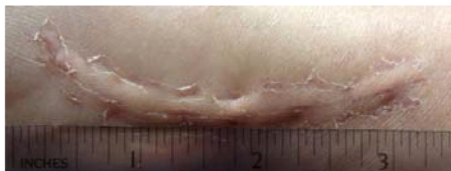


Figure 3. Patient new ankle scar (before PracaSil-Plus)

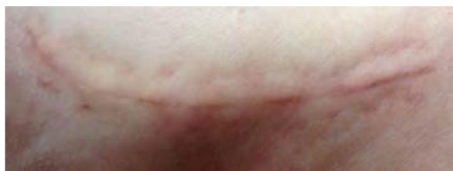

Figure 4. Patient new ankle scar (two weeks after PracaSil-Plus)

Patient Report: *The results have been fantastic. The scar is very smooth and it has reduced in size over time. At the end of two weeks, the scar was considerably flattened and wearing a sock did not irritate the area.*

Acknowledgements: Both patients agreed to anonymously share the information and figures included in this case study. Figures 1 - 4 are courtesy of the patients. PCCA Science is grateful for the valuable information shared.

Introduction: PracaSil-Plus is a proprietary anhydrous silicone base designed to be applied topically in scar therapy treatment (PCCA, 2013a). Silicones have been widely used for their occlusion and hydration properties, which are essential in scar management (Widgerow *et al.*, 2000; Mustoe, 2008). PracaSil-Plus also contains Pracaxi oil, extracted from the oilseed plant *Pentaclethra macroloba*, which has several medicinal applications including skin regeneration and healing (Costa *et al.*, 2013). PracaSil-Plus may be used alone or as a base for the incorporation of active substances in scar therapy treatment (PCCA, 2013a).

Research Studies: The efficacy of PracaSil-Plus in scar therapy treatment was evaluated by visual and instrumental methods in an eight-week, randomized, double-blind, controlled pilot trial conducted on eleven adult Caucasian subject volunteers. PracaSil-Plus showed qualitative and quantitative improvements in the following scar attributes: scar length, scar color/pigment intensity, scar texture/smoothness/roughness, and overall appearance in both old scars and new scars (PCCA, 2013b).

References:

- Costa, M., Muniz, M., Negrao, C., Costa, C., Lamarao, M., Morais, L., Junior, J. and Costa, R. (2013) 'Characterization of *Pentaclethra macroloba* oil', *Journal of Thermal Analysis and Calorimetry*, 16 January 2013 [Online].
- Mustoe, T. (2008) 'Evolution of silicone therapy and mechanism of action in scar management', *Aesthetic Plastic Surgery*, 32 (1), p.82-92.
- PCCA (2013a) *PracaSil-Plus*. Available at: <http://www.pccarx.com/pcca-products/pcca-exclusives/bases/PracaSil-plus> (Accessed: 17 May 2013).
- PCCA (2013b) 'Efficacy of PracaSil-Plus in scar therapy treatment: a randomized, double-blind, controlled pilot trial', *Technical Report: 2TR0513*.
- Widgerow, A., Chait, L., Stals, R. and Stals, P. (2000) 'New innovations in scar management', *Aesthetic Plastic Surgery*, 24 (3), p.227-234.



Click the QR to see more
PCCA studies and
reports.